

Wacky Eye Movements: Deadly, Debilitating or Dubious?

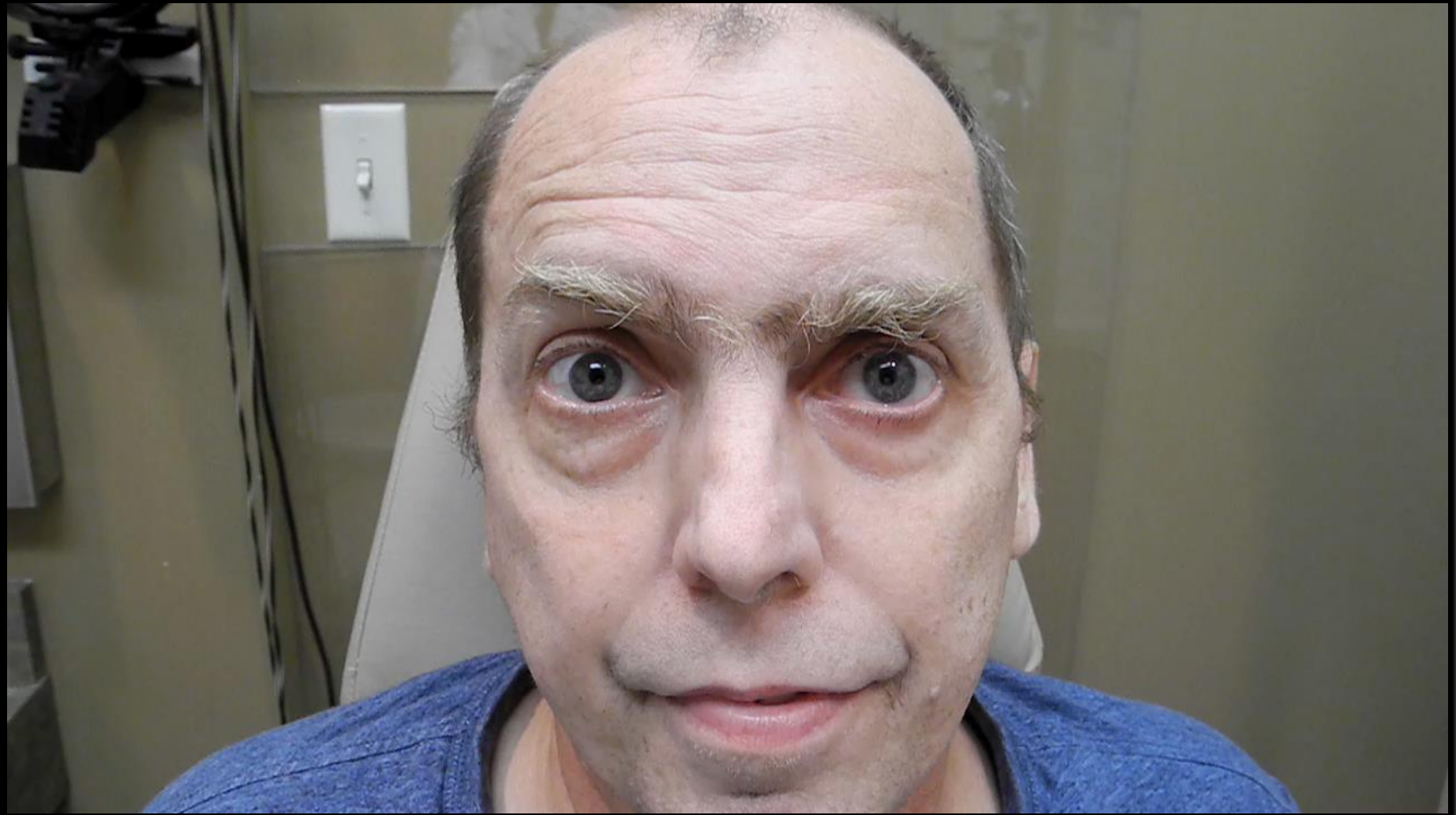Orbis Cybersight Webinar, April 24, 2018

Karl C. Golnik, MD, MEd



Objectives:

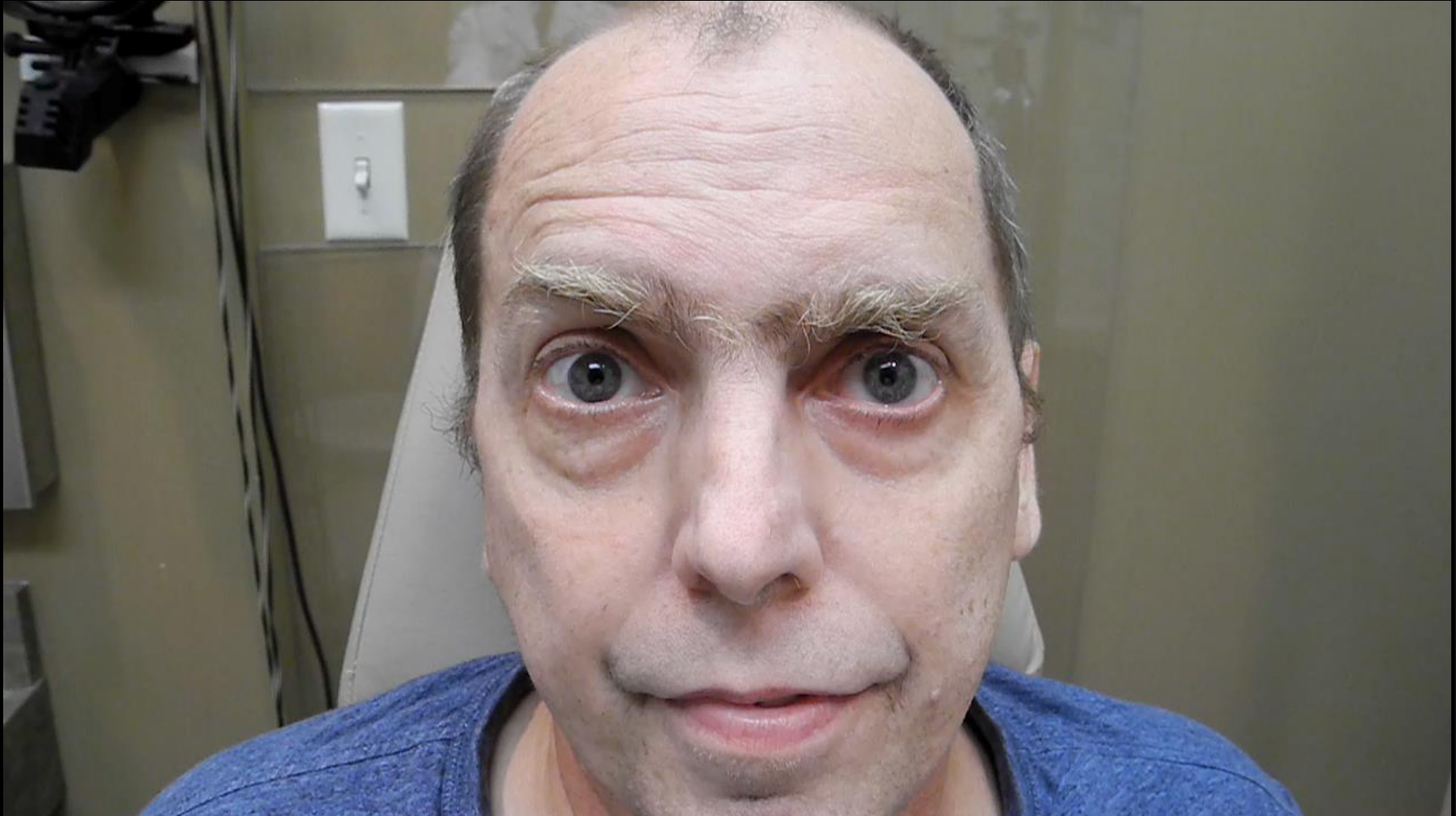1. Identify at least 3 uncommon pathognomonic patterns of eye movements.
2. Determine appropriate testing for these entities.



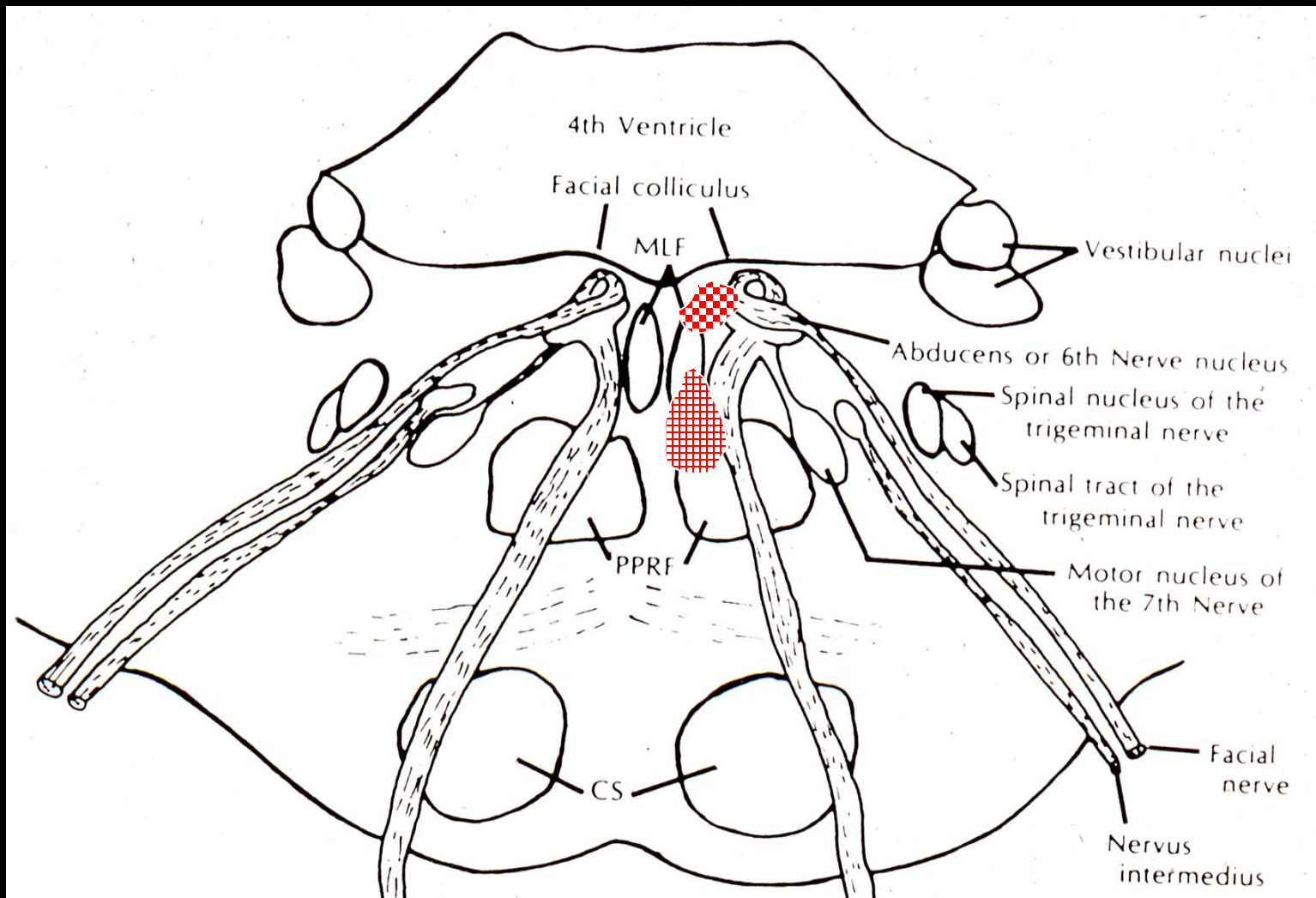
What is this syndrome called?

- A. Weber
- B. One and a half
- C. Parinaud
- D. Wallenberg

1 & ½ Syndrome

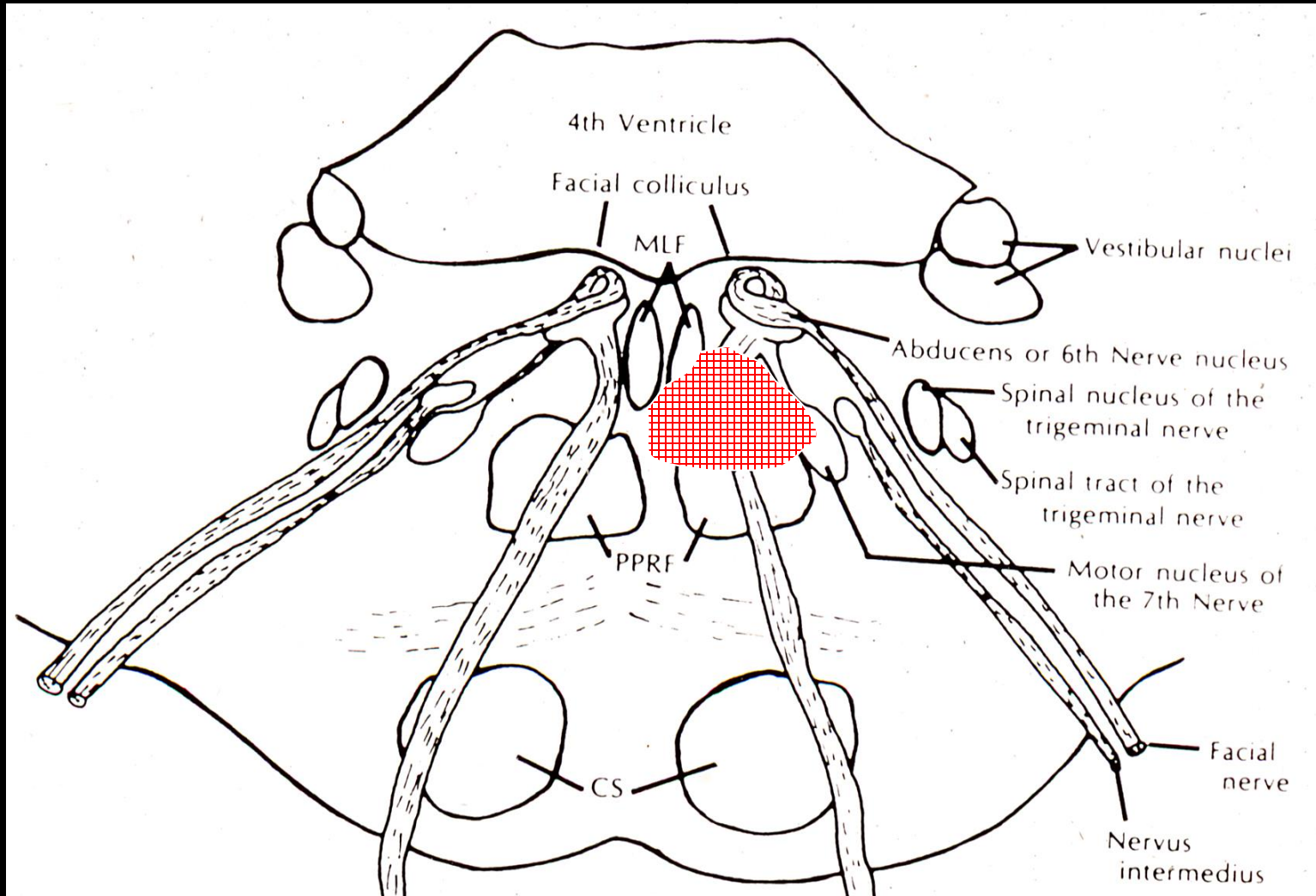


Deadly (or Debilitating)



1 and 1/2 syndrome

8 and 1/2 syndrome?





What is going on here!?

- A. Myasthenia gravis
- B. Transient cranial nerve palsy
- C. Ocular Neuromyotonia
- D. No idea!

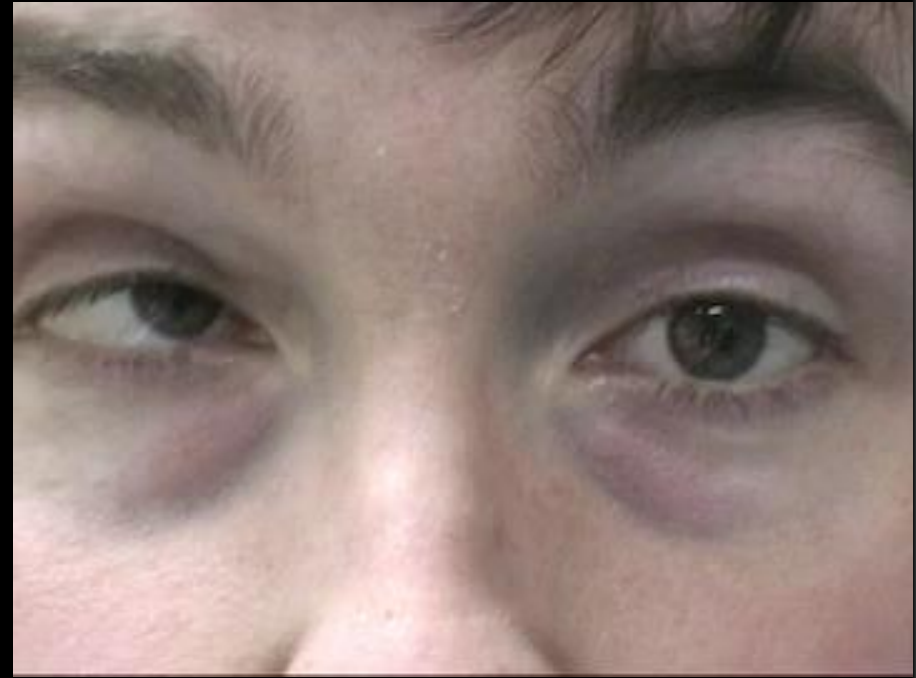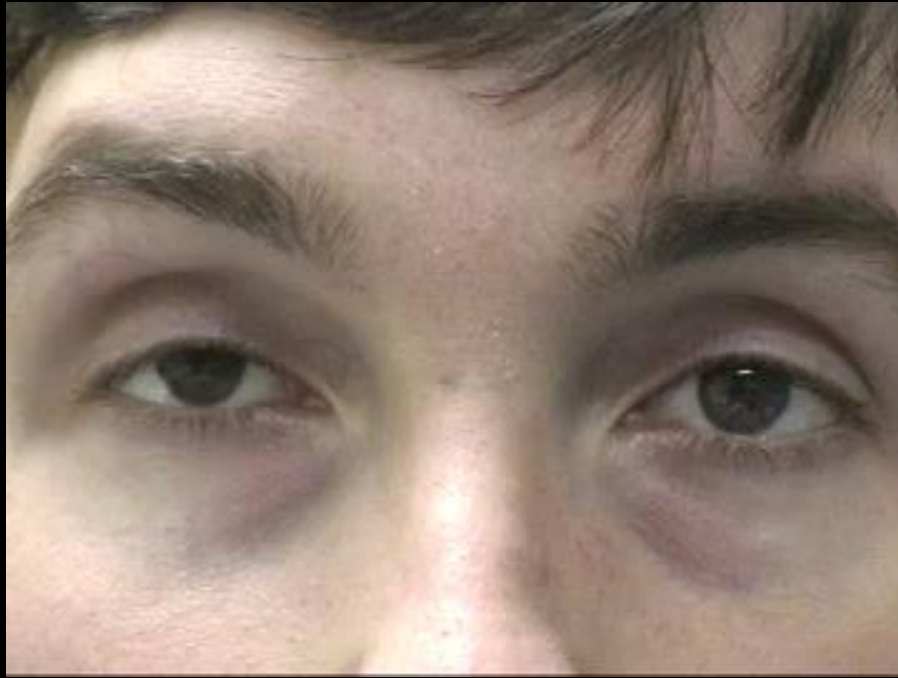Ocular Neuromyotonia



Associated with prior radiation, vascular compression, TED

Debilitating

Ocular Neuromyotonia



Associated with prior radiation, vascular compression, TED

Debilitating



Appropriate evaluation in an 8-year-old?

- A. MRI head
- B. Lumbar puncture
- C. Acetylcholine receptor antibodies
- D. Urine catecholamines

Opsoclonus (myoclonus/ataxia)



Neuroblastoma or Post-Infectious
Deadly (maybe!)



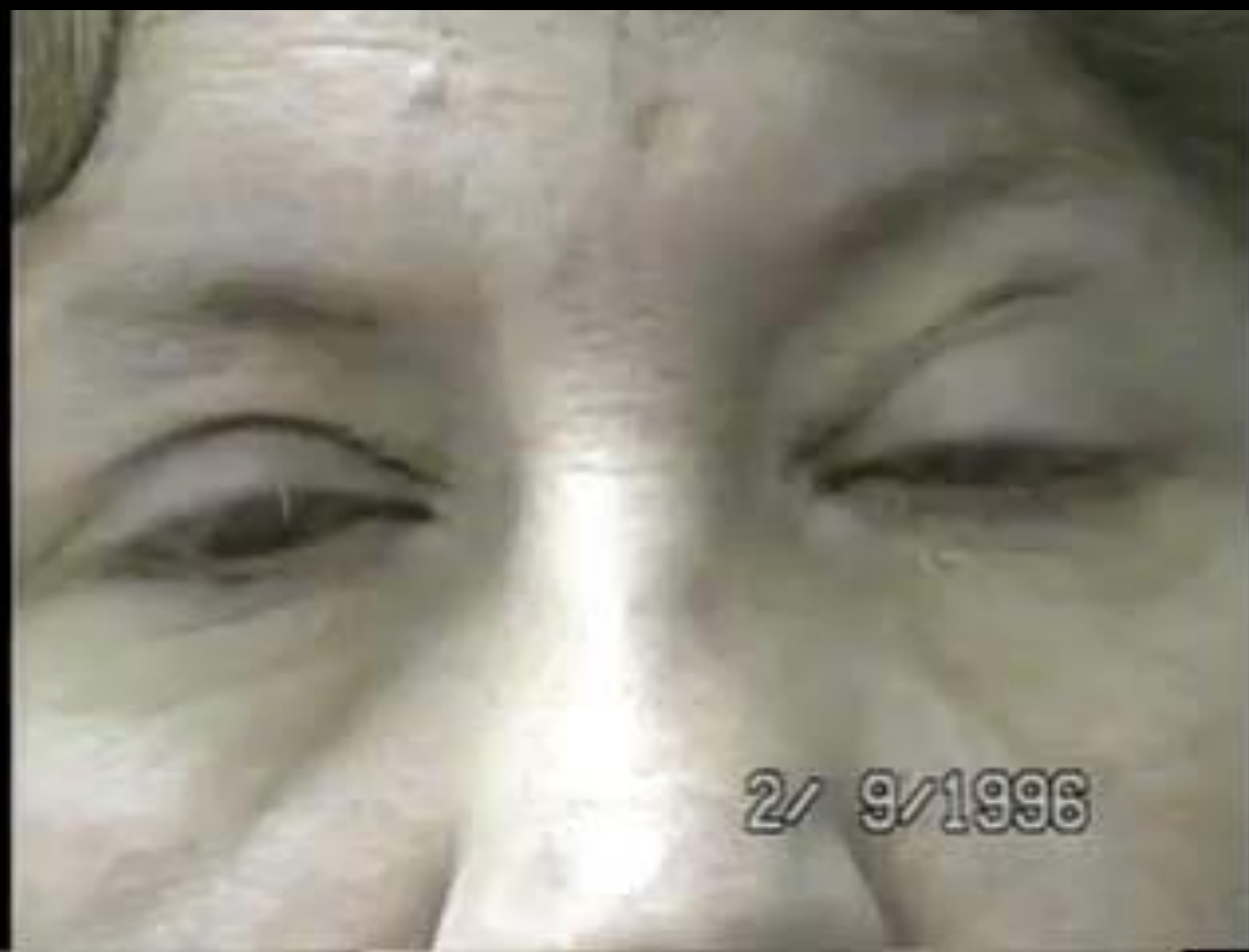Diagnosis?

- A. Bilateral 4th nerve palsies
- B. Myasthenia gravis
- C. Thyroid eye disease
- D. None of the above

Bilateral 4th N palsy



Debilitating

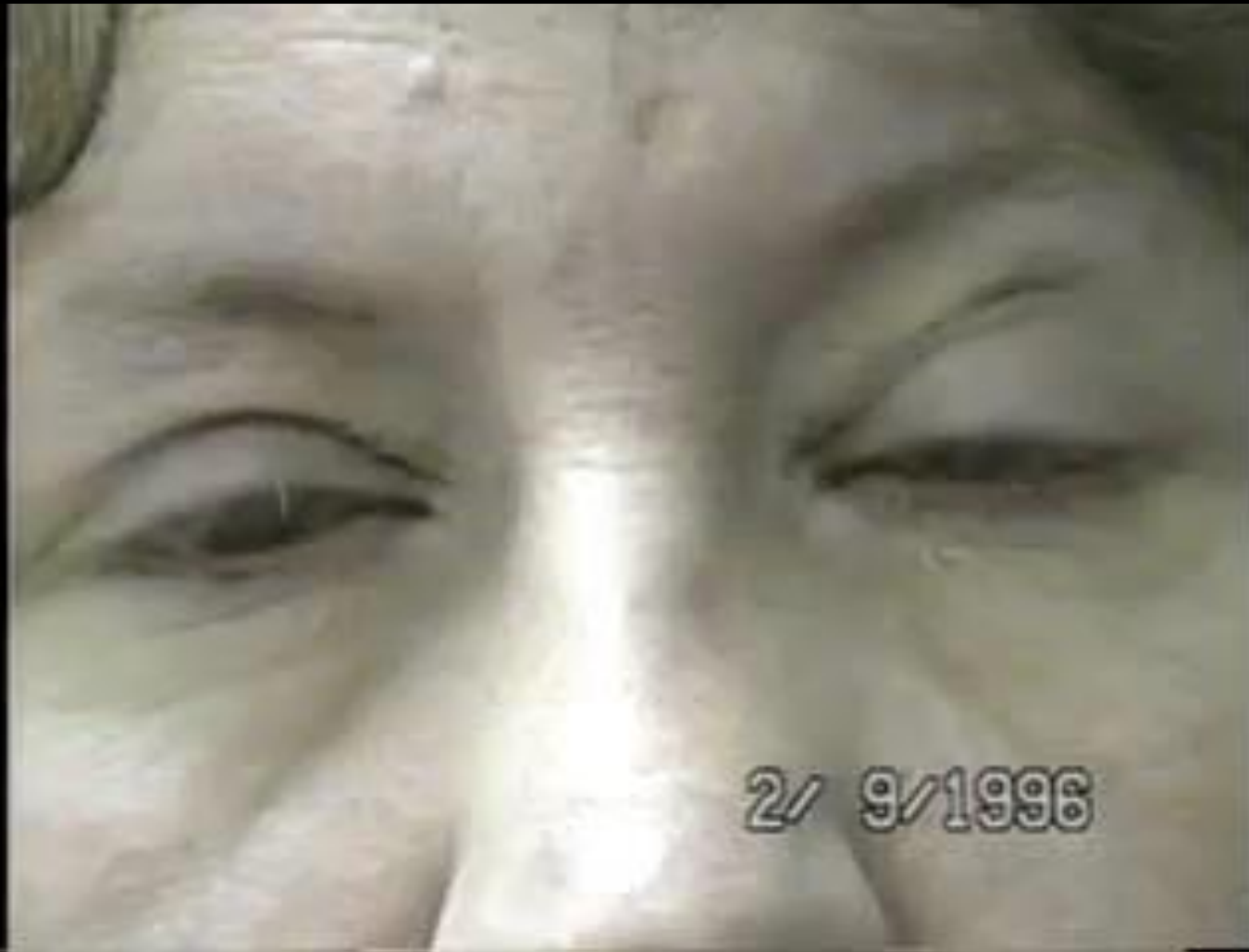

2/ 9/1996

Diagnosis?

- A. Bilateral 6th nerve palsies
- B. Myasthenia gravis
- C. Thyroid eye disease
- D. Spasm of the near reflex

Spasm of the Near Reflex



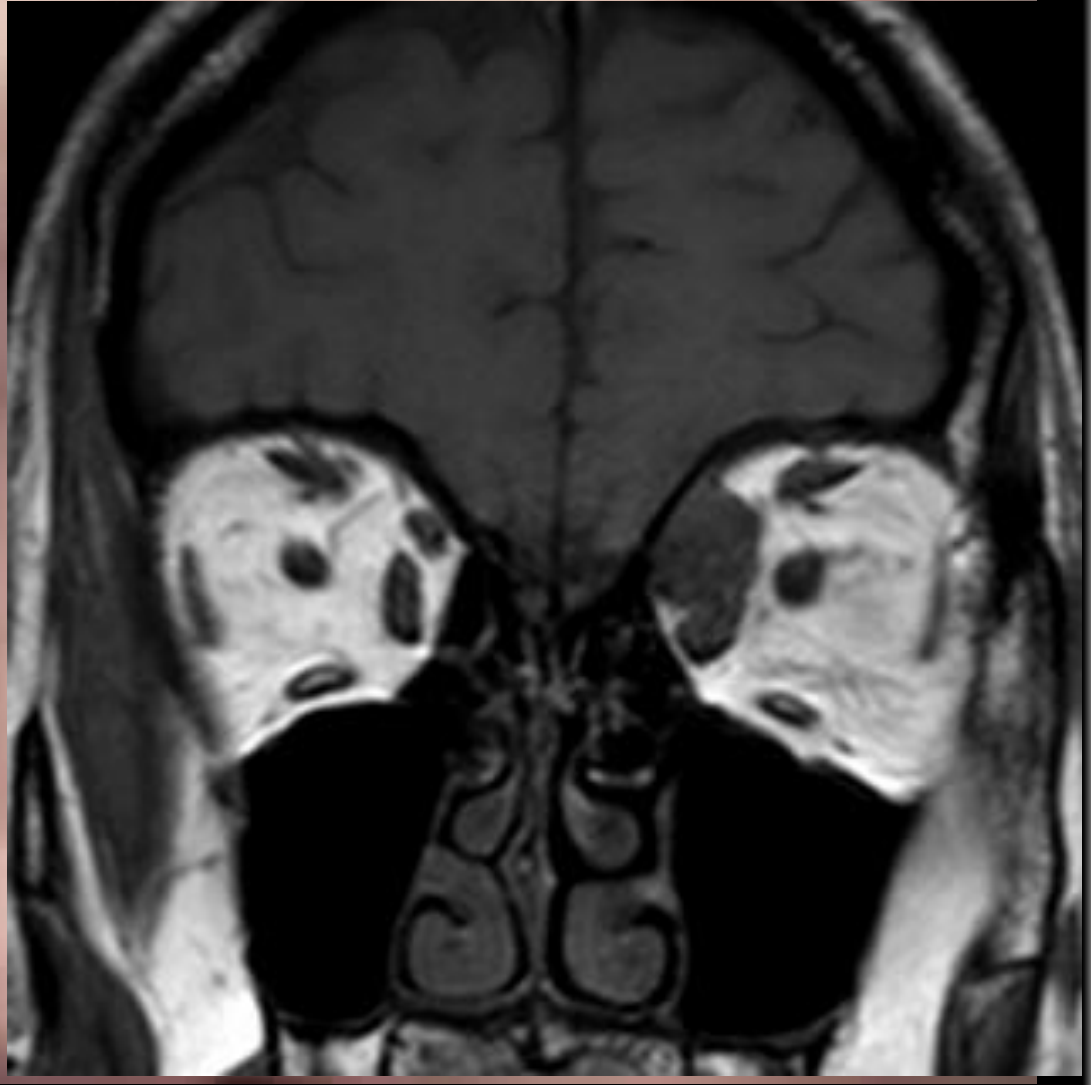
Debilitating

Cycloplegics, Psychiatric therapy?, Refractive Lens Exchange!?

Party Trick



Dubious!



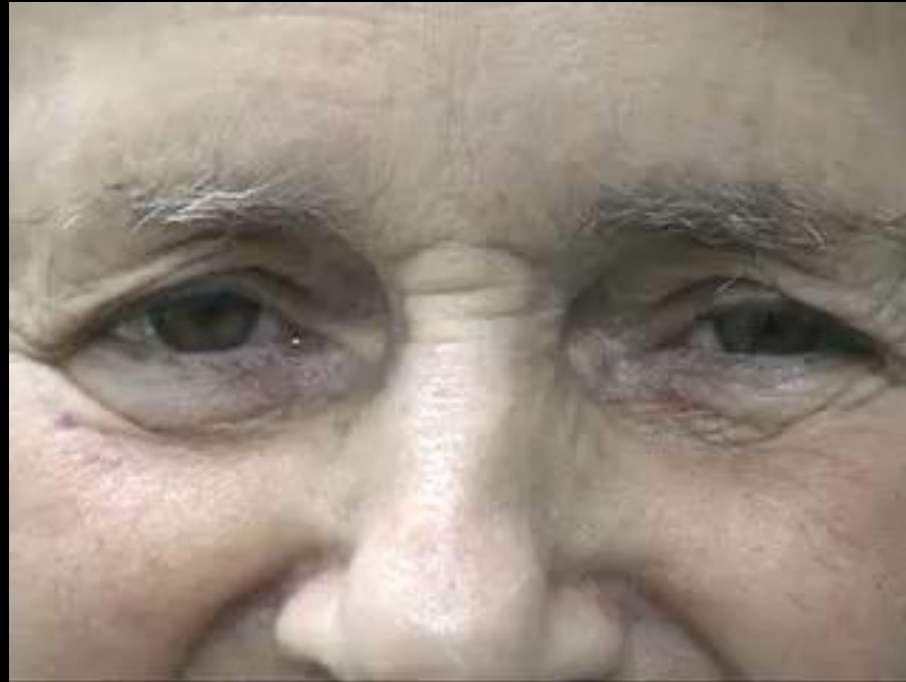Deadly



Diagnosis?

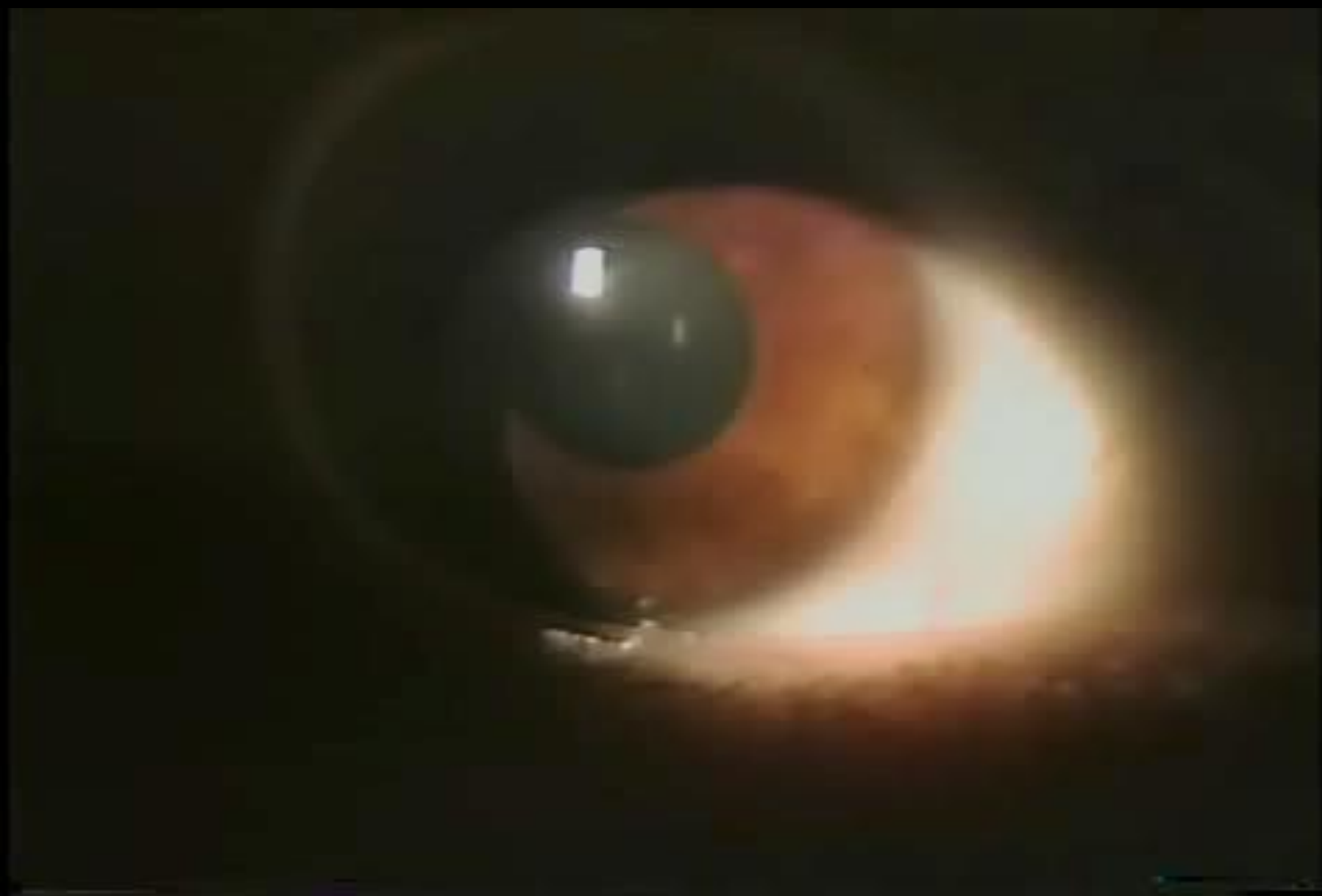- A. CPEO
- B. Guillain-Barre
- C. Myasthenia gravis
- D. Thyroid eye disease

Anti-GQ1b Ab Syndrome aka Miller-Fisher



Triad: ophthalmoplegia, areflexia and ataxia

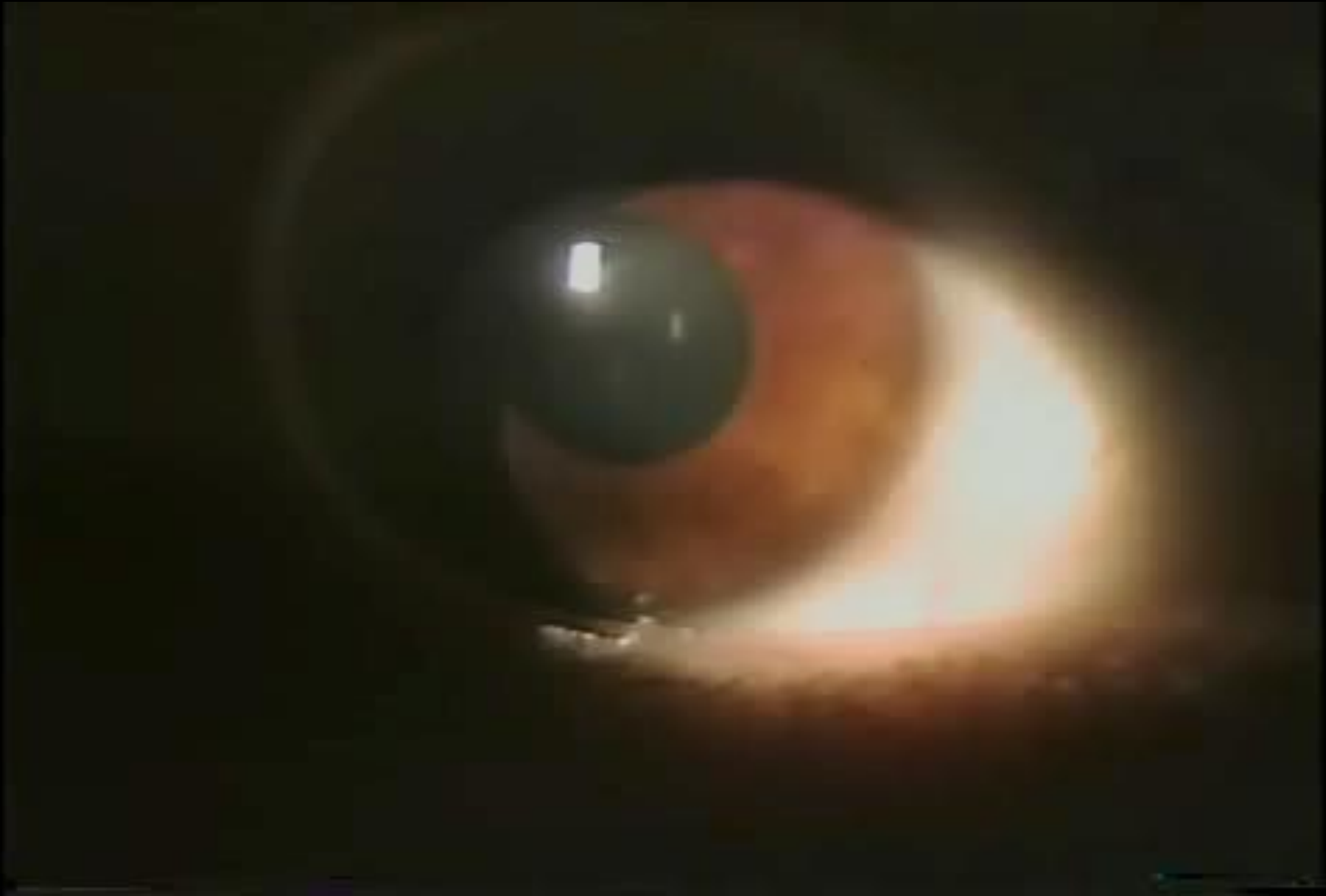Debilitating



Diagnosis?

- A. Opsoclonus
- B. Superior oblique myokymia
- C. Downbeat nystagmus
- D. 4th n palsy

Superior Oblique Myokymia



Debilitating

3rd Nerve Aberrant Regeneration



Debilitating

Marcus Gunn Jaw-Winking



Dubious!

Misdirection between 3 & 4?



What is this syndrome called?

- A. Weber
- B. One and a half
- C. Parinaud
- D. Wallenberg

Lateropulsion in Wallenberg Syndrome (Lateral Medullary Syndrome)



Deadly! (maybe)

Summary

- There are a variety of pathognomonic eye movement disorders
- Some are a nuisance but some can be deadly.
- Thus recognizing these patterns is essential!

Thank-you for your attention.